Downloaded from UvA-DARE, the institutional repository of the University of Amsterdam (UvA)
http://dare.uva.nl/document/124244

File ID	124244
Filename	Chapter 5 The long-term outcome of the cemented Weber acetabular component in total hip replacement using a second-generation cementing technique

SOURCE (OR PART OF THE FOLLOWING SOURCE):

Type	Dissertation
Title	Clinical and experimental aspects of fixation, loosening, and revision of total hip replacement
Authors	P.T. de Jong, F.H.R. de Man
Faculty	Faculty of Medicine
Year	2009
Pages	319

FULL BIBLIOGRAPHIC DETAILS:
http://dare.uva.nl/record/293608

Copyright

It is not permitted to download or to forward/distribute the text or part of it without the consent of the author(s) and/or copyright holder(s), other then for strictly personal, individual use.

UvA-DARE is a service provided by the library of the University of Amsterdam (http://dare.uva.nl)

Chapter 5

The long-term outcome of the cemented Weber acetabular component in total hip replacement using a second-generation cementing technique.

P.T. de Jong, MD
F.H.R. de Man, MD*
D. Haverkamp, MD, PhD**
R.K. Marti, MD, PhD**

Sint Jansdal Ziekenhuis, Department of Orthopaedic Surgery, Harderwijk, The Netherlands
* Sint Maartenskliniek, Department of Orthopaedics, Nijmegen, The Netherlands
** Academic Medical Center, Department of Orthopaedic Surgery, Amsterdam, The Netherlands

ACCEPTED FOR PUBLICATION BY THE BRITISH JOURNAL OF BONE AND JOINT SURGERY

Abstract

We report the long-term outcome of a modified second generation cementing technique for fixation of the acetabular component of total hip replacement. An earlier study has shown the superiority of this technique assessed by improved survival compared with first generation cementing.
The acetabular preparation involved reaming only to the subchondral plate, followed by impaction of bone into the anchorage holes.
Between 1978 and 1993, 287 total hip replacements were undertaken in 244 patients, with a mean age of 65.3 years (21-90) using a hemispheric Weber acetabular component with this modified technique for cementing and a cemented femoral component.
The survival with acetabular revision for septic loosening as the endpoint was 99.1% (95% confidence interval (CI) 97.9 to 100) after ten years, and 85.5% (95% CI 74.7 to 96.2) at twenty years.
Apart from contributing to a long lasting fixation of the component, this technique also preserved bone, facilitating revision surgery when necessary.

Introduction

The debate on cemented versus uncemented acetabular components in total hip replacement (THR) continues. Although some authors suggest abandoning the use of cemented implants[1], others show good survival rates of 90% after 25 years[2]. Survival rates in these studies vary, but the common conclusion is that aseptic loosening is the main cause for revision in cemented acetabular components. The Scandinavian arthroplasty registers[3-6] show that in young patients, there is no significant difference in the overall survival rate with revision as endpoint, between uncemented and cemented cups. For all-polyethylene cups the 10-year survival was 87% (95%CI: 85%-90%) and for porous-coated uncemented cups 88% (95%CI: 85%-90%). Aseptic loosening was the main reason for revision when cemented cups were used. Uncemented components were also exchanged for other reasons, such as polyethylene wear and osteolysis.

Aseptic loosening is influenced by the cementing technique used[7], and it seems clear that this needs to be optimizsed. Several reports have been published on improvements in the technique of cementing the femoral component[8-12], but only a few papers have addressed the acetabular side[13-17].

We modified the cementing technique for the acetabular component in 1978. This was first presented at a symposium in 1982 and published in 1983[13]. It was anticipated by the senior author (RKM) that it would improve the survival of the implant, and this has been demonstrated by comparing survival rates of patients before and after 1978 in our earlier study[18]. We now again describe this method and the long-term results. We also compared our results to the long-term outcome of other cemented acetabular components reported in the literature.

Materials and Methods

Patients

Between 1978 and 1993, the senior author performed 287 total hip replacements (THR) in 244 patients, 65 of whom were men, using a hemispherical Weber socket (Allopro®, Baar Switzerland) implanted with a technique developed by him. In order to obtain a clear view of the outcome using this technique the number of variables were reduced by excluding operations performed by orthopaedic trainees and those where any other acetabular component was used. The mean age at the time of surgery was 65.3 years (21-90). The reason for the THR was idiopathic osteoarthritis in 140 hips, osteoarthritis secondary to dysplasia in 96, rheumatoid arthritis in eight, avascular necrosis of the femoral head in 23, posttraumatic osteoarthritis in 13, and other secondary osteoarthritis in seven. Previous surgery had been performed in 73 hips and included an intertrochanteric osteotomy in 56 patients, a pelvic osteotomy in two, a shelf plasty in two, and an internal fixation because of a proximal femoral or acetabular fracture in 13.

Operative technique and implants

All procedures were done with antibiotic prophylaxis, using an anterolateral approach with the patient in the supine position. The Weber Rotation (Allopro, Baar, Switzerland) THR was used as a standard implant in all primary cases. The stem was manufactured from Protasul® 10 alloy (Sulzer AG, Wintherthur, Switzerland) with a cylindrical trunnion made of Protasul® 2 (Sulzer AG) which permits rotation. To this trunnion 32 mm heads were attached, of which 100 were made of Protasul® 2 and 187 of ceramic (Biolox®, Feldmühle, Plochingen, Germany). The head was placed on the rotating Protasul® 2 cylinder, which was available in three lengths (42 mm, 47 mm and 52 mm). The Weber hemispherical acetabular component was used in every patient. This all-polyethylene component

(RCH-1000 Chirulen®, Hoechst, Germany) was available with an external diameter ranging between 40 to 64 mm, of which the depth varied between 24 to 37 mm. The rim of the acetabular component had a scalloped profile. The advantage of this profile was to allow partial or complete removal of the prominences giving a perfect fit of the component in the reamed acetabulum, creating intrinsic stability before cementing (Fig 1).

The interrupted shape also allowed compression of the cement between the prominences using a special impaction device during polymerisation of the cement. A 47 mm diameter component was used in 62 hips (21.6 %), the 52 mm in 179 hips (62.4%), the 57 mm in 44 hips (15.3%) and the 64 mm in two (0.7%).

Fig 1. *Adaptation of the rim of the cup for a perfect fit.*

Cementing technique

Our technique for cementing the acetabular component involves reaming the acetabulum to the depth of the subchondral layer, making multiple (6-8) anchorage holes, which are conical in shape and have a diameter of 8 mm. Only the hard superficial bone of the subchondral plate is drilled. The cancellous bone beneath the anchorage holes is impacted instead of being removed, using a specially designed round-ended impactor with a diameter of 8 mm. Anchorage holes are produced to a depth of 0.5 cm to 1.5 cm, depending on the softness of the bone (Fig 2). This method lines the holes with a homogeneous layer of cancellous bone.

Fig 2. *Impacting and drilling of the anchorage holes.*

When the quality of the cancellous bone is poor and subchondral cysts are present, cancellous bone from the femoral head is impacted into the anchorage holes. In the presence of a very sclerotic acetabulum, a 6 mm drill is used to roughen the bony surface in between the holes.

For implantation of the acetabular component the anchorage holes are dried and filled with multiple gauze swabs. The swabs are removed, quickly followed by digital introduction of low viscosity Sulfix® cement (Sulzer AG, Wintherthur, Switzerland) into the holes, to avoid any bleeding between the cancellous bone and the cement, creating optimal compression of the cement-bone interface. The cement is not handled until initial polymerisation has commenced and it is losing its stickiness. This can be determined by the cement losing its shiny surface, which generally occurs after six to eight minutes. The cement must reach this phase to permit proper compression. The polyethylene acetabular component is then introduced and the cement is primarily compressed in the direction of the craniolateral anchorage holes. Shortly afterwards, anteversion and inclination are corrected, still under compression. By pressing the component in the craniolateral direction first, extrusion of cement on the medial side can usually be avoided and a high pressurisation of the cement into the important anchorage holes is achieved. Approximately 40% of the full 40 g mix of cement is usually required to achieve good fixation.

A trochanteric osteotomy was performed in 48 hips. In 91 hips, bony coverage of the acetabular component was insufficient, which required the addition of an acetabular shelf plasty[19].

Follow-up

The patients were seen at regular intervals, with an initial post-operative visit after six weeks, and then at three, six, and 12 months, two years and then biennially thereafter. The follow-up consisted of radiological and clinical evaluation. The Harris Hip Score[20] was used to assess the clinical outcome. For the radiological analysis, weight-bearing anteroposterior (AP) pelvic and lateral X-rays were obtained and were scrutinized for radiological signs of loosening using the criteria described by Harris[11] for the stem and the criteria described by Hodgkinson[21] for the acetabular component.

A descriptive analysis was performed for the complications, clinical and radiological follow-ups. Survival analysis was calculated using the life-table method. The primary endpoints were revision for radiologically-proven aseptic loosening of the acetabular component and radiological evidence of loosening. Secondary endpoints included revision for any reason, revision for aseptic loosening of the femoral component, revision for loosening of either one of the components and definitive

signs of radiological loosening of the femoral component. To evaluate the success of this technique in the younger and more active patient, we divided the group of 278 hips into patients under 55 years of age (n=39 hips) and those above that age (n=239 hips) and analysed them separately.

Results

Aseptic loosening necessitated isolated revision of the acetabular component in four patients. Eight patients had revision surgery for aseptic loosening, during which both components were exchanged. Two patients had septic loosening of their components, resulting in the removal of both components. At the latest follow-up, 107 patients (117 hips) of the 224 unrevised patients had died at an average of 9.6 years after surgery (range 0.01 to 25). Two patients died shortly after surgery as result of a myocardial infarction. In total 35 patients (44 hips) were considered lost to follow up, but were included in the survival analysis and radiological analysis until their last regular check at an average of 7.9 years (range 0.1 to 18.6) after surgery. A total of 21 hips in 20 patients were revised.

Interval (years)	Number entering interval	Number with-drawn	Deaths	Number at risk	Number with aseptic loose-ning	survival	SE
0-1	287	16	3	278	0	1	0
1-2	268	5	7	262	0	1	0
2-3	256	1	2	255	0	1	0
3-4	253	2	5	250	0	1	0
4-5	246	2	2	244	0	1	0
5-6	242	5	7	236	1	0.996	0.0042
6-7	229	4	4	225	0	0.996	0.0042
7-8	221	9	2	216	1	0.991	0.0062
8-9	209	10	7	201	0	0.991	0.0062
9-10	192	5	10	185	0	0.991	0.0062
10-11	177	16	5	167	1	0.9852	0.0086
11-12	155	6	10	147	0	0.9852	0.0086
12-13	139	15	6	129	1	0.9775	0.0114
13-14	117	12	4	109	1	0.9686	0.0144
14-15	100	22	2	88	1	0.9575	0.018
15-16	75	13	3	67	1	0.9433	0.0227
16-17	58	6	1	55	1	0.9259	0.0281
17-18	50	5	2	47	0	0.9259	0.0281
18-19	43	9	1	38	0	0.9259	0.0281
19-20	33	8	6	26	2	0.8547	0.0549
20-21	17	6	0	14	2	0.7326	0.0928

Table I. *Life table analysing the survival data of the 287 hips, with revision for aseptic loosening of the acetabular component as endpoint.*

Apart from the cup revisions, five patients needed a revision of the stem. In these cases, the acetabular component was left in place. One patient had a revision of the stem after 9.1 years without revision of the acetabular component, which was revised 10 years later (19.1 years after the primary procedure). One stem was revised because of a peri-prosthetic femoral fracture (14.1 years after implantation). In two patients, septic loosening was the cause for revision of both components.

With revision for aseptic loosening of the acetabular component as endpoint, we found a 10-year survival rate of 99.1% (95% CI: 97.9-100), a 15-year survival rate of 95.7% (95% CI: 92.2-99.3) and a 20-year survival rate of 85.5% (95% CI: 74.7-96.2) (Table 1, Fig. 3).

The survival of the acetabular component in the patients less than 55 years of age with revision for aseptic loosening as the endpoint was 97.1% (91.4-100) at 10 years, dropping to 81.7% (64.6-98.7) at 16 years, when 14 hips were at risk. (Table 2)

Interval (years)	Number entering interval	Number with-drawn	Deaths	Number at risk	Number with aseptic loose-ning	survival	SE
0-1	39	1.0	0.0	38.5	0	1	0
1-2	38	0.0	0.0	38.0	0	1	0
2-3	38	0.0	0.0	38.0	0	1	0
3-4	38	0.0	0.0	38.0	0	1	0
4-5	38	0.0	0.0	38.0	0	1	0
5-6	38	0.0	2.0	37.0	0	1	0
6-7	36	0.0	0.0	36.0	0	1	0
7-8	36	0.0	0.0	36.0	0	1	0
8-9	36	0.0	0.0	36.0	0	1	0
9-10	36	0.0	0.0	36.0	0	1	0
10-11	36	4.0	0.0	34.0	1	0.971	0.029
11-12	31	0.0	0.0	31.0	0	0.971	0.029
12-13	31	3.0	1.0	29.0	0	0.971	0.029
13-14	26	2.0	0.0	25.0	1	0.932	0.047
14-15	23	7.0	1.0	19.0	1	0.883	0.065
15-16	14	1.0	0.0	13.5	1	0.817	0.087
16-17	12	3.0	0.0	10.5	0	0.817	0.087
17-18	9	0.0	0.0	9.0	0	0.817	0.087
18-19	9	3.0	0.0	7.5	0	0.817	0.087
19-20	6	3.0	0.0	4.5	0	0.817	0.087
20-21	3	2.0	0.0	2.0	0	0.817	0.087

Table 2. *Life table analyzing the survival data of 39 hips in patients under the age of 55, with revision for aseptic loosening of the cup as endpoint.*

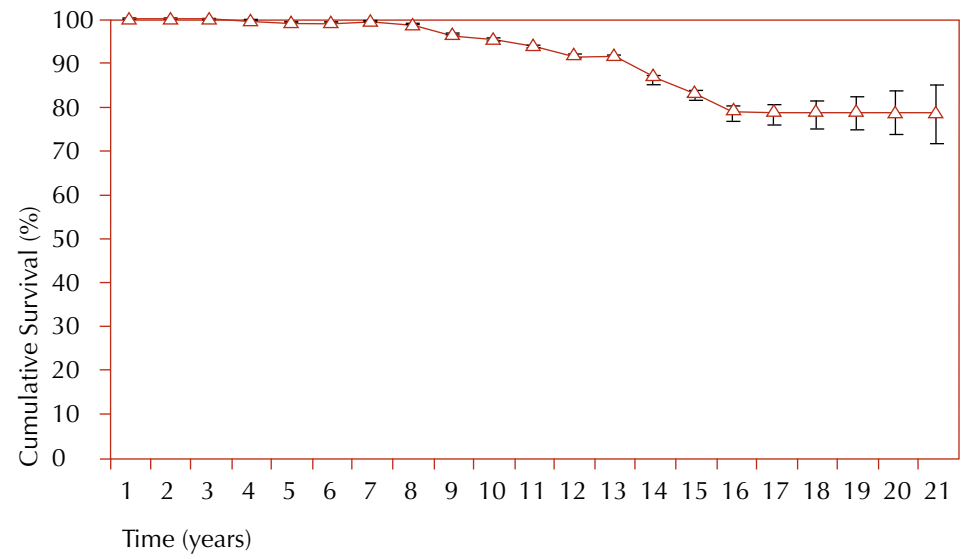

Figure 3a. *Graphic presentation of survival.*

Revision for aseptic loosening of the acetabular component.

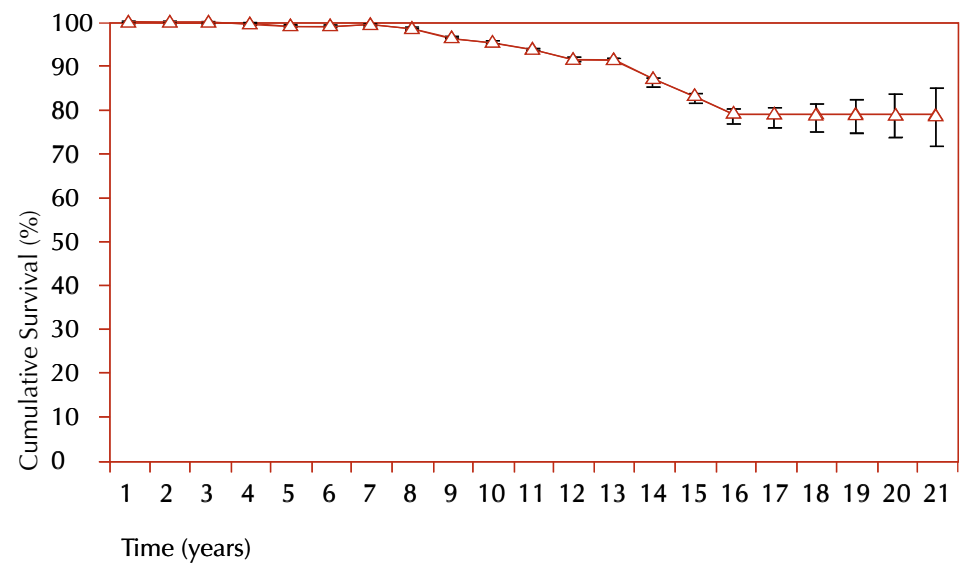

Figure 3b. *Graphic presentation of survival.*

Revision for aseptic loosening or radiological signs of probable/definitive loosening of the acetabular component.

Radiological survival analysis revealed twelve acetabular components showing signs of possible loosening after an average of 15.4 years (range 8.4-22.9). No cups showed signs of definitive loosening (Fig 3).

Radiographs of the femoral components showed six cases with possible signs of loosening after a mean of 16 years (13.2 to 19.3), one with probable signs of loosening after 22.9 years, and five with definitive signs of loosening after a mean of 16.5 years (9.2 to 20.4). This survival for all the hips at various endpoints is presented in Table 3. In all, four patients needed a second operation without exchange of either prosthesis, one because of severe heterotopic ossification causing ankylosis and three because of non-union after osteotomy of the greater trochanter.

The Harris hip score (HHS) was obtained from 93 patients (112 hips) after an average of 14.9 years (range 10.0 to 23.7). The average score was 91.5 (range 24 to 100). HHS was under 70 in 4 hips, 71 to 80 in 10 hips, 81 to 90 in 27 hips, and 90 to 100 in 71 hips.

The total number of per- or peri-operative complications, was 22. Two femoral shafts were perforated during surgery This was recognised but needed no additional action because the damage was only minor. In six THRs a crack occurred at the greater trochanter, in five of which there had been a previous intertrochanteric osteotomy. The problem was resolved by reattaching the greater trochanter with screws and cerclage wiring.
There were two sciatic nerve palsies, which both made a full recovery.
A haematoma developed in nine hips, five of which were treated with surgical debridement. Two wound infections healed with antibiotics and surgical debridement. One hip dislocated 14 year post-operatively, and remained stable after closed reduction.

	Survival		
Endpoint	**10 year**	**15 year**	**20 year**
Revision of either component for any reason	95.1% (92.3-98.0%)	89.2% (84.1-94.3%)	80.5% (70.5-90.5%)
Revision for aseptic loosening of the cup	99.1% (97.9-100%)	95.7% (92.2-99.3%)	85.5% (74.7-96.2%)
Revision for aseptic loosening of either component	97.2% (94.9-99.4%)	93.1% (88.8-97.3%)	83.8% (73.5-94.0%)
Cup revision for any reason	98.7% (97.3-100%)	94.6% (90.7-98.5%)	84.4% (73.7-95.2%)
Revision of the cup or radiological possible/ definitive loosening	98.1% (96.3-99.9%)	91.8% (87.1-96.5%)	71.0% (58.4-83.6%)

Table 3. *Survival rates with different endpoints.*

Discussion

Our study shows that excellent long-term results can be obtained with cemented acetabular components when using our cementing technique.

A recent meta-analysis of studies comparing cemented and uncemented fixation in THR has shown that cemented fixation still outperforms uncemented fixation in large subsets of the study populations[22]. Although cementless fixation of acetabular components seems to reduce the rate of aseptic loosening, it has been reported that loosening of these devices frequently coincides with more extensive loss of acetabular bone[23-25]. Polyethylene wear and osteolysis have caused concern in uncemented acetabular components[14,26-28].

Apart from wear debris as a causative factor in peri-acetabular osteolysis, it is proposed that stress shielding from a metal backed device may contribute to bone resorption around the acetabular implant [29-31]. Earlier studies showed a more uniform distribution of stresses to the periprosthetic bone with metal-backed compo-

nents [32], but more recent work describes an apparent mismatch between the elastic modulus of the metal backing and the peri-prosthetic bone, as well as a difference in structural stiffness of the implant[33,34].

A 3-D finite element study by Manley, Ong and Kurz[35] showed a more even distribution of stresses in the model using polyethylene rather than chrome-cobalt metal-backed implants. The model suggested that with the use of polyethylene as an implant, peripheral bone resorption would occur, but with the potential for bone formation at the dome.

Our reported survival rate for the cemented Weber cup using our cementing technique and the latest results of the Charnley acetabular component[36], indicate that there is still room for the use of a cemented acetabular component.

An important step in our cementing technique is the impaction of cancellous bone into the anchorage holes. This reduces bleeding from the bone and assists in the production of a dependable cement mantle.

We used finger-packing to insert the cement into the anchorage holes of the reamed acetabulum. Only one randomised prospective study using radiostereophotogrammetic analysis (RSA) compares finger-packing with a pressurisation technique [37]. It showed that the pressurisation method was superior to finger-packing. However, the method of finger-packing analysed is not completely comparable to our method, in which low-viscosity cement is used at a relatively late stage, so that it performs like a high viscosity cement, allowing digital pressurisation into each keying hole. Flivik et al[37] pressurized each individual anchorage hole with a special device before pressurising the cement in the reamed acetabulum. In their finger-packing group, the anchorage holes were not separately filled with cement, but the whole acetabulum filled with a cement gun and then digitally compressed. The impacted bone in the anchorage holes and the preservation of the subchondral layer prevents cement from leaking into the peri-acetabular cancellous bone. We believe this preserves the elasticity modulus of the bone around the implant, and when acetabular component loosening prevails, limited destruction of bone stock occurs.

The role of the anchorage holes was investigated by Mootanah et.al [38] using a finite element analysis. They showed that depth and size of the anchorage holes were of

less importance than their inclination, and showed the optimal anchorage hole to be perpendicular to the acetabulum. This is the technique we employ.
We used both ceramic and metal heads, but have not analysed these separately. However, we do not believe this to have resulted in any difference in outcome. Although Schuller and Marti[39] showed a difference in the amount of wear between these two heads, it was established in an earlier study that this did not lead to a significant difference in the rate of loosening[18].

Our study shows that excellent results can be obtained with hemispheric all-polyethylene cemented cups. Unfortunately, the described Weber component with an interrupted rim and the Weber Rotation stem are no longer available. We anticipate similar results from the Weber fix system, although it has been proved to produce more wear in comparison to the Rotation system[40]. We believe that our cementing technique offers dependable acetabular fixation in cemented THR, with preservation of bone stock.

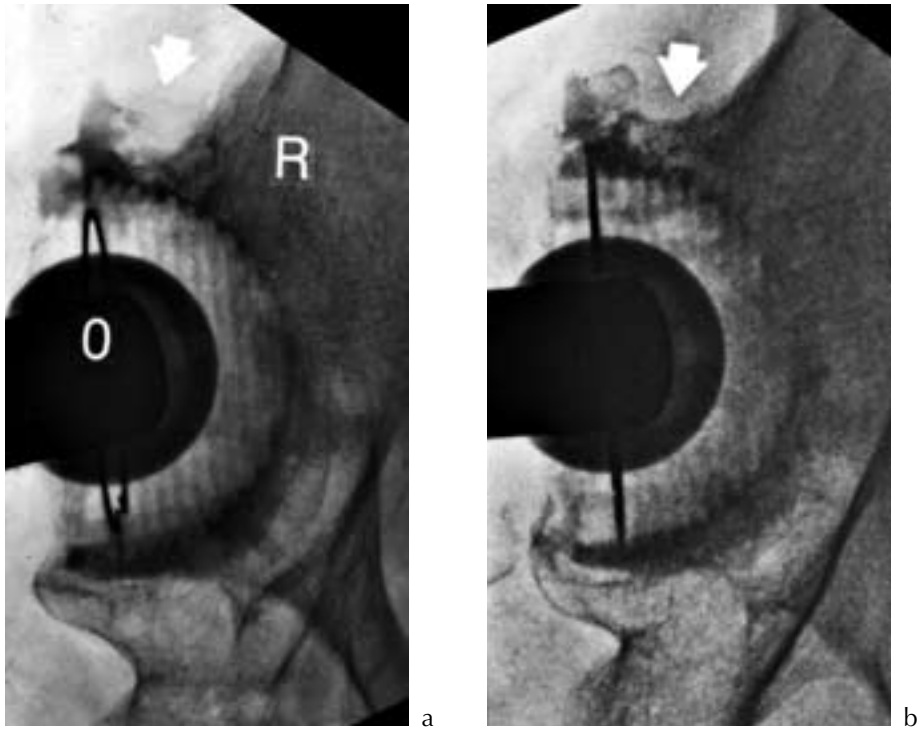

Fig.5 a and b *Radiographs of a 68-year old female patient .*
Postoperative LAT radiograph (a) and LAT radiograph at 23-year follow-up (b). Note the apposition of bone in b.

References

1. **Ritter MA, Thong AE.** The role of cemented sockets in 2004: is there one? *J Arthroplasty 2004;19-4 Suppl 1:92-4.*
2. **Berry DJ, Harmsen WS, Cabanela ME, Morrey BF.** Twenty-five-year survivorship of two thousand consecutive primary Charnley total hip replacements: factors affecting survivorship of acetabular and femoral components. *J Bone Joint Surg Am 2002;84-A-2:171-7.*
3. **Havelin LI, Engesaeter LB, Espehaug B, Furnes O, Lie SA, Vollset SE.** The Norwegian Arthroplasty Register: 11 years and 73,000 arthroplasties. *Acta Orthop Scand 2000;71-4:337-53.*
4. **Lucht U.** The Danish Hip Arthroplasty Register. *Acta Orthop Scand 2000;71-5:433-9.*
5. **Malchau H, Herberts P, Eisler T, Garellick G, Soderman P.** The Swedish Total Hip Replacement Register. *J Bone Joint Surg Am 2002;84-A Suppl 2:2-20.*
6. **Puolakka TJ, Pajamaki KJ, Halonen PJ, Pulkkinen PO, Paavolainen P, Nevalainen JK.** The Finnish Arthroplasty Register: report of the hip register. *Acta Orthop Scand 2001;72-5:433-41.*
7. **Ranawat CS, Deshmukh RG, Peters LE, Umlas ME.** Prediction of the long-term durability of all-polyethylene cemented sockets. *Clin Orthop Relat Res 1995-317:89-105.*
8. **Mulroy WF, Harris WH.** Acetabular and femoral fixation 15 years after cemented total hip surgery. *Clin Orthop Relat Res 1997-337:118-28.*
9. **Mulroy RD, Jr., Harris WH**. The effect of improved cementing techniques on component loosening in total hip replacement. An 11-year radiographic review. *J Bone Joint Surg Br 1990;72-5:757-60.*
10. **Barrack RL, Mulroy RD, Jr., Harris WH.** Improved cementing techniques and femoral component loosening in young patients with hip arthroplasty. A 12-year radiographic review. *J Bone Joint Surg Br 1992;74-3:385-9.*
11. **Harris WH, McCarthy JC, Jr., O'Neill DA.** Femoral component loosening using contemporary techniques of femoral cement fixation. *J Bone Joint Surg Am 1982;64-7:1063-7.*
12. **Pierson JL, Harris WH.** Effect of improved cementing techniques on the longevity of fixation in revision cemented femoral arthroplasties. Average 8.8-year follow-up period. *J Arthroplasty 1995;10-5:581-91.*

13. **Marti RK, and Besselaar PP.** Bone Grafts in Primary and Secondary Total Hip replacement. *Amsterdam: Exerpta Medica, 1983:107-29.*
14. **Ranawat CS, Peters LE, Umlas ME**. Fixation of the acetabular component. The case for cement. *Clin Orthop Relat Res 1997-344:207-15.*
15. **Malchau H, Herberts P, Ahnfelt L.** *P*rognosis of total hip replacement in Sweden. Follow-up of 92,675 operations performed 1978-1990. *Acta Orthop Scand 1993;64-5:497-506.*
16. **Weber BG.** Technique and Results of Primary and revision Arthroplasty of the Hip Joint:Pressurization of Bone Cement. In: Marti RK, ed. Progress in Cemented Total Hip Surgery and Revision. *Amsterdam: Elsevier Science Publishers BV, 1983:87-93.*
17. **Weber BG.** Pressurized cement fixation in total hip arthroplasty. *Clin Orthop Relat Res 1988-232:87-95.*
18. **de Jong PT, van der Vis HM, de Man FH, Marti RK.** Weber rotation total hip replacement: a prospective 5- to 20-year followup study. *Clin Orthop Relat Res 2004-419:107-14.*
19. **de Jong PT, Haverkamp D, van der Vis HM, Marti RK.** Total hip replacement with a superolateral bone graft for osteoarthritis secondary to dysplasia: a long-term follow-up. *J Bone Joint Surg Br 2006;88-2:173-8.*
20. **Harris WH.** Traumatic arthritis of the hip after dislocation and acetabular fractures: treatment by mold arthroplasty. An end-result study using a new method of result evaluation. *J Bone Joint Surg Am 1969;51-4:737-55.*
21. **Hodgkinson JP, Shelley P, Wroblewski BM.** The correlation between the roentgenographic appearance and operative findings at the bone-cement junction of the socket in Charnley low friction arthroplasties. *Clin Orthop Relat Res 1988-228:105-9.*
22. **Morshed S, Bozic KJ, Ries MD, Malchau H, Colford JM, Jr**. Comparison of cemented and uncemented fixation in total hip replacement: a meta-analysis. *Acta Orthop 2007;78-3:315-26.*
23. **Crowther JD, Lachiewicz PF.** Survival and polyethylene wear of porous-coated acetabular components in patients less than fifty years old: results at nine to fourteen years. *J Bone Joint Surg Am 2002;84-A-5:729-35.*
24. **Barrack RL, Folgueras A, Munn B, Tvetden D, Sharkey P.** Pelvic lysis and polyethylene wear at 5-8 years in an uncemented total hip. *Clin Orthop Relat Res 1997-335:211-7.*
25. **Berger RA, Jacobs JJ, Quigley LR, Rosenberg AG, Galante JO.** Primary cementless acetabular reconstruction in patients younger than 50 years old. 7- to 11-year results. *Clin Orthop Relat Res 1997-344:216-26.*
26. **Hernandez JR, Keating EM, Faris PM, Meding JB, Ritter MA.** Polyethylene wear in uncemented acetabular components. *J Bone Joint Surg Br 1994; 76-2:263-6.*
27. **Nieuwenhuis JJ, Malefijt Jde W, Hendriks JC, Gosens T, Bonnet M.** Unsatisfactory results with the cementless Omnifit acetabular component due to polyethylene and severe osteolysis. *Acta Orthop Belg 2005; 71-3:294-302.*
28. **Gaffey JL, Callaghan JJ, Pedersen DR, Goetz DD, Sullivan PM, Johnston RC.** Cementless acetabular fixation at fifteen years. A comparison with the same surgeon's results following acetabular fixation with cement. *J Bone Joint Surg Am 2004;86-A-2:257-61.*
29. **Wright JM, Pellicci PM, Salvati EA, Ghelman B, Roberts MM, Koh JL.** Bone density adjacent to press-fit acetabular components. A prospective analysis with quantitative computed tomography. *J Bone Joint Surg Am 2001;83-A-4:529-36.*
30. **Mueller LA, Kress A, Nowak T, Pfander D, Pitto RP, Forst R, Schmidt R.** Periacetabular bone changes after uncemented total hip arthroplasty evaluated by quantitative computed tomography. *Acta Orthop 2006;77-3:380-5.*
31. **Schmidt R, Muller L, Kress A, Hirschfelder H, Aplas A, Pitto RP.** A computed tomography assessment of femoral and acetabular bone changes after total hip arthroplasty. *Int Orthop 2002;26-5:299-302.*
32. **Carter DR, Vasu R, Harris WH.** Stress distributions in the acetabular region--II. Effects of cement thickness and metal backing of the total hip acetabular component. *J Biomech 1982;15-3:165-70.*
33. **Widmer KH, Zurfluh B, Morscher EW.** Load transfer and fixation mode of press-fit acetabular sockets. *J Arthroplasty 2002;17-7:926-35.*
34. **Morscher E, Berli B, Jockers W, Schenk R**. Rationale of a flexible press fit cup in total hip replacement. 5-year followup in 280 procedures. *Clin Orthop Relat Res 1997-341:42-50.*
35. **Manley MT, Ong KL, Kurtz SM.** The potential for bone loss in acetabular structures following THA. *Clin Orthop Relat Res 2006;453:246-53.*
36. **Wroblewski BM, Siney PD, Fleming PA.** Charnley low-friction arthroplasty: survival patterns to 38 years. *J Bone Joint Surg Br 2007;89-8:1015-8.*

37. **Flivik G, Sanfridsson J, Onnerfalt R, Kesteris U, Ryd L.** Migration of the acetabular component: effect of cement pressurization and significance of early radiolucency: a randomized 5-year study using radiostereometry. *Acta Orthop 2005;76-2:159-68.*

38. **Mootanah R, Ingle P, Dowell J, Cheah K, Shelton JC.** Fixation of the acetabular cup in cemented total hip replacement: improving the anchorage hole profile using finite element method. *Technol Health Care 2000;8-6:343-55.*

39. **Schuller HM, Marti RK.** Ten-year socket wear in 66 hip arthroplasties. Ceramic versus metal heads. *Acta Orthop Scand 1990;61-3:240-3.*

40. **van der Vis HM, Zwartele R, Schuller HM, Doets HK, Marti RK.** Socket wear in ceramic-on-polyethylene total hip arthroplasties: fixed versus rotating heads. *Acta Orthop Scand 1998;69-3:248-52.*